

Bilateral Metachronous Breast Cancer

Sunil V. Jagtap¹, Suresh J. Bhosale², Gayatri N. Patel³, Swati S. Jagtap⁴

¹Professor, Department of Pathology, ²Professor, Department of Surgery, ³Assistant Lecturer, Department of Pathology, ⁴Associate Professor, Department of Physiology, Krishna Institute of Medical Sciences, Deemed to be University, Karad, Maharashtra 415110, India.

Abstract

Introduction : Bilateral breast cancer is extremely rare presentation. Most of the cases of bilateral breast cancer are of lobular carcinoma type. Herewith we report a case of bilateral Invasive Breast Carcinoma (Not Otherwise specified). A case of a 47 year old female who presented with bilateral breast mass, right breast mass measuring 3.4 x 2 x 2 cm and left breast mass measuring 2.8x2.0x1.6 cm. Fine needle aspiration cytology of right breast mass was reported as positive for carcinoma cells. Patient was operated for left modified radical mastectomy 8.5 years back which was reported as Invasive Breast Carcinoma (IBC) - II and now, the patient was operated for right modified radical mastectomy which was reported as right sided Invasive Breast Carcinoma with medullary differentiation. The Richardson Bloom score was (3+3+3) =9, Grade III. *Conclusion*: Metachronous bilateral breast cancer is an extremely rare presentation of breast cancer. Early detection of contralateral breast tumor is of utmost importance for appropriate management of these cases.

Keywords: Bilateral Breast Cancer; Invasive Breast Carcinoma; Breast Lump; Medullary Differentiation.

Corresponding Author:

Sunil Vitthalrao Jagtap, Professor,
Department of Pathology, Krishna Institute
of Medical Sciences, Deemed to be University,
Karad, Maharashtra 415110, India.

E-mail: drsvjagtap@gmail.com

Received on 30.11.2018,

Accepted on 28.12.2018

How to cite this article:

Sunil V. Jagtap, Suresh J. Bhosale, Gayatri N. Patel et al. Bilateral Metachronous Breast Cancer. Indian J Pathol Res Pract. 2019;8(1):122-125.

Introduction

The first description of synchronous Bilateral Breast Cancer (BBC) was reported by Kilgore in 1921. He described simultaneous diagnosis of tumors in both the breasts [1]. BBC is an uncommon presentation with an incidence of 2-5% of all breast malignancies [2,3]. The time interval of first

cancer and second cancer can be synchronous or metachronous. Synchronous cancer is defined by various interval from 1 month to 1 year [4,5]. Synchronous bilateral breast cancers (SBC) was defined as two tumors diagnosed within an interval of 6 months while a second cancer diagnosed after 6 months is considered as metachronous breast cancer (MBC). Synchronous breast cancers

constitute about 0.2-3% incidence of all newly diagnosed breast cancers . MBC has a cumulative incidence of 12% [6,7].

There are controversies about the origin of second cancer whether it is from metastatic spread or from an independent primary. Herewith, we are present a case of Metachronous BBC with respect to its clinical and histopathological aspects as well as the overall prognosis of the patient.

Case Presentation

A 47 year old female presented with right sided breast mass since 1 month duration. She was a known case of Invasive breast carcinoma –grade II on left side (Fig 1,2) diagnosed 8.5 years back and operated for Modified Radical Mastectomy (MRM) . She received 6 cycles of chemotherapy and radiotherapy for the same. Presently she was operated for right Modified Radical Mastectomy, of which we received the specimen of wide excision - right breast lump totally measuring 6.6 x 5.6 x 3.7 cm and weighing 300 grams. On serial cut sections it revealed a single, large, irregular, grey white, firm tumor measuring 3.4 x 2 x 2 cm. Adjacent breast tissue appeared unremarkable. Totally 16 right axillary lymph nodes were resected, out of which two lymph nodes showed tumor infiltration with perinodal spill. On histological examination it was reported as right sided Invasive breast carcinoma with medullary differentiation. The Richardson Bloom score was (3+3+3) =9 Grade III (Fig 3,4,5).

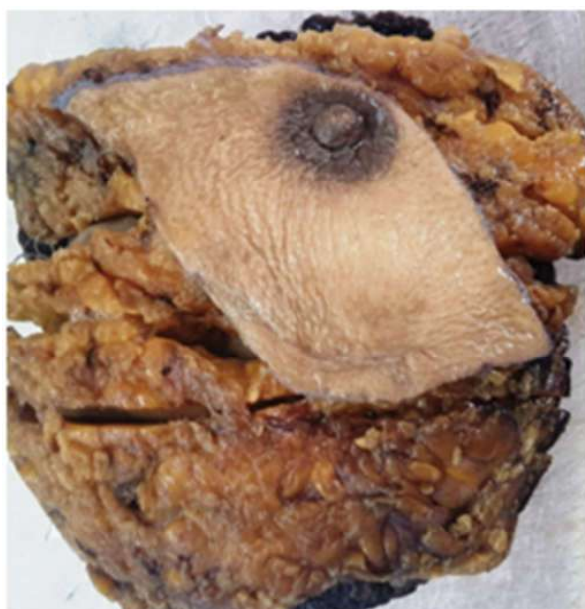

Fig. 1: Gross specimen of left breast modified radical mastectomy.

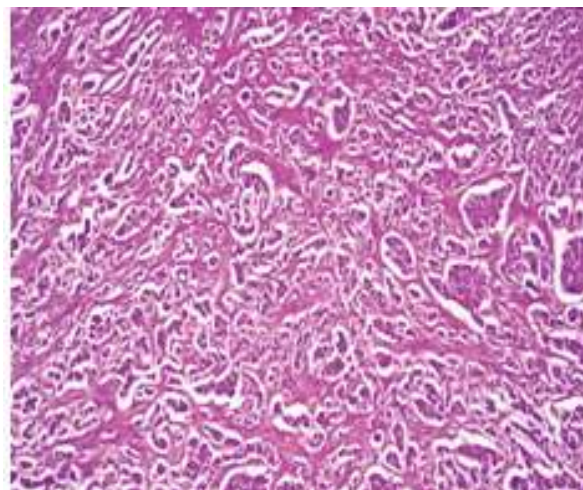


Fig. 2: Photomicrograph showing invasive breast carcinoma grade II. (H&E stain, 40X)

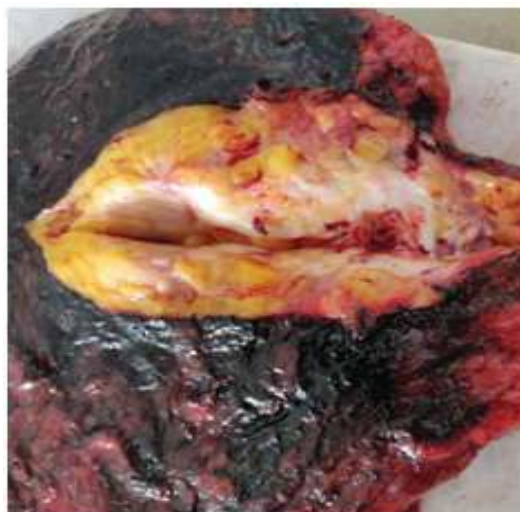

Fig. 3: Gross specimen of right breast modified radical mastectomy. Cut section showing grey white

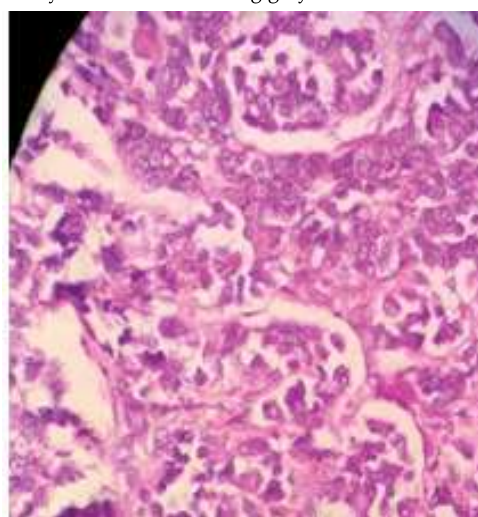


Fig. 4: Photomicrograph showing invasive breast carcinoma grade III. (H&E stain, 100X)

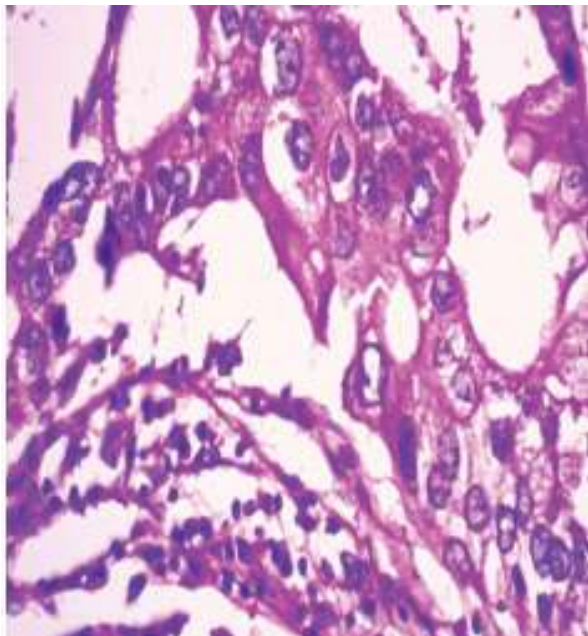


Fig. 5: Photomicrograph showing invasive breast carcinoma grade III with areas of medullary differentiation and stroma showing lymphoplasmacytic infiltration. (H&E stain, 100X).

Discussion

There is increasing incidence of BBC as a result of improved diagnostic modalities. The contralateral breast mammography examination in newly diagnosed breast cancers and improvement of life expectancy with breast cancer treatment are responsible for this rise in incidence. In young patients the relative risk of developing metachronous breast cancer is higher.

The median age for synchronous breast cancer is younger (under 50 years) as compared to unilateral breast cancer (mean 63 year) [3]. There is significant family history reported in BBC (30-39%) as compared to unilateral breast cancer (5%) [8]. There are various etiological factors for development of BBC such as positive family history, genetic predisposition, younger age at diagnosis of the first primary, lobular variant, nulliparity have been better described [9,10]. Synchronous BBC is an extremely rare condition to be detected in male breast [11]. The histopathological type detected in BBC is mostly of invasive breast carcinoma (NOS) accounting for 60-73% while lobular type accounts for (10-16%) of total cases, others being 7-8% of total cases [12]. In our case both the cancers are of IBC type. The Second primary was detected after a prolonged duration. Second primary showed IBC with medullary differentiation. It is stated that use of adjuvant chemotherapy significantly reduces the

risk of metachronous breast carcinoma. However in our case inspite of receiving chemotherapy she developed BBC. Coradini et al reported there is no significant difference in ER/PR/Her2 neu status between BBC and unilateral breast carcinoma [13]. It is noted that ER/PR negative tumors are reported to be risk factor for contra lateral breast cancer. In our case the ER/PR was positive, while Her2 neu was negative.

There are no clear guidelines for treatment of BBC. These patients are usually undergo bilateral mastectomy. The study by Jia Jian Chen showed no statistical significance for the population of patients who received adjuvant chemotherapy or endocrine therapy [12].

These womens with BBC have comparatively higher mortality from breast cancers than with the womens who present with Unilateral Breast Carcinoma. It is observed that in breast cancer patients there is continuously improving survival status related to early detection and effective therapy, so most of these cases have an increased risk of developing of second malignancies. Therefore identification of subsequent effect of breast cancer and its treatment is very challenging.

Conclusion

The occurrence of second malignancy in a breast cancer survival patient is growing rapidly . In our case it showed primary invasive breast carcinoma initially and after a period of 8.5 year period it developed second breast cancer of invasive breast carcinoma with medullary differentiation.

References

1. Kilgore AR. The incidence of cancer in second breast: after radical removal of one breast for cancer. *JAMA*. 1921;77(6):454-7.
2. Heron DE, Komarnicky LT, Hyslop T, Schwartz GF, Mansfield CM. Bilateral breast carcinoma: Risk factors and outcomes for patients with synchronous and metachronous disease. *Cancer*. 2000;88: 2739-50.
3. Shi YX, Xia Q, Peng RJ, Yuan ZY, Wang SS, et al. Comparison of clinicopathological characteristics and prognosis between bilateral and unilateral breast cancer. *Journal of Cancer Research and Clinical Oncology*. 2012;138(4):705-14.
4. Gollamudi SV, Gelman RS, Peiro G, Schneider LJ, Schitt SJ, Recht A, et al. Breast conserving therapy for stage i-II synchronous bilateral breast carcinoma. *Cancer*. 1997;79(7):1362-69.

5. Vuoto HD, et al. Bilateral breast carcinoma : clinical characteristics and its impact on survival. *Breast J.* 2010;16(6):625-32.
 6. Elrasheid A. H. Kheirelseid, Hanzali Jumustafa, Nicola Miller, Catherine Curran, Karl Sweeney, et al. Bilateral breast cancer: analysis of incidence, outcome, survival and disease characteristics. *Breast Cancer Research and Treatment, Springer Verlag.* 2010;126(1):131-40.
 7. Intra M, Rotmensz N, Viale G, Mariani L, Bonanni B, Mastropasqua MG, et al. Clinicopathologic characteristics of 143 patients with synchronous bilateral invasive breast carcinomas treated in a single institution. *Cancer.* 2004;101:905-12
 8. Kelmendi de Ustaran J, Meiss RP. Primary synchronous bilateral breast cancer:epidemiological approach. *Breast Cancer Res Treat.* 1988;12(3):311-14.
 9. Kheirelseid EA, et al. Bilateral Breast cancer: analysis of incidence, outcome, survival and disease characteristics. *Breast Cancer Res Treat.* 126(1):131-140.
 10. Chen Y, Thmopson W, Semenciw R, Mao Y. Epidemiology of contralateral breast cancer . *Cancer Epidemiol Biomarkers Prev.* 1999;8:855-861.
 11. Jagtap SV, Chougule PG, Khatib W, Shukla DB, Jagtap SS. Male breast cancer: presenting as synchronous, large, bilateral masses. *Journal of Clinical and Diagnostic Research. JCDR:* 2014;8(4) FD07.
 12. Jia-jian Chen, Yan Wang, Jing-yan Xue, Ying Chen, et al . Synchronous Bilateral Breast Cancer: A Retrospective Evaluation and Prospective Validation of Potential Risk Factors. *PLOS ONE.* 2014;9(4):e95185
 13. Coradini D, Oriana S, Mariani L, Miceli R, Bresciani G, Marubini E, Di Fronzo G Is steroid receptor profile in contralateral breast cancer a marker of independence of the corresponding primary tumour? *European Journal of Cancer.* 1998;34:825-30.
-